

Mark L. Miller and J. Eric Gordon

Introduction

Lower extremity deformities can vary widely with regard to their etiology, magnitude, integrity of the soft-tissue envelope, and natural history. Because of this variation, it is difficult to create a formulaic method of approaching the patient with a lower limb deformity. This difficulty is compounded by differences in the patient's environment, surgeon's skills, resources available to treat the patient, and ability of the patient or family to comply with a treatment program. Because of these differences, it is important to assess how each of these factors may influence the treatment method that is ultimately chosen and to follow a consistent approach in analyzing the deformity and planning the surgical correction. The nature and location of the deformity should guide the surgeon's choice of implant, not vice versa.

When approaching lower extremity deformities, it is important to develop a comprehensive problem list outlining the pathology associated with the involved limb. In some situations these lists may be quite short, outlining only a simple uniplanar angulatory deformity. In other situations, however, these lists can be quite complex, combining multiple deformities in different planes and locations, soft-tissue issues, joint instability, and psychological and family issues that can be extremely challenging.

It is important to remember that even with a consistent approach to decision making, it is not uncommon that multiple approaches to similar clinical deformities and symptoms may be appropriate and that there may not be a single "best" approach. Surgeon skills and patient/caretaker preferences can often influence the final decision making in these

situations and it is important that the surgeon discuss the various options and potential complications with the patient and/or family prior to making a final decision.

Clinical Evaluation

When evaluating a patient, there is a temptation for surgeons to look at radiographs of the patient and make decisions regarding the ultimate treatment without taking into account other factors. Like other areas of medicine, it is important for the surgeon to obtain a history of the problem, perform a careful physical examination, and obtain appropriate laboratory studies and imaging prior to making a diagnosis and developing a treatment plan.

When obtaining a history, it is important to elicit from the patient or family a chronologic account of the development of the deformity as well as current symptoms of pain, instability, and functional limitations. The surgeon should understand the limitations that the patients and their caretakers perceive as well as their expectations of treatment. The presence of joint instability, limitation of motion, pain, neurologic symptoms, signs of infection, and previous treatment are crucial to elicit from the patient or family. Past medical history, such as coagulopathy or bleeding issues, compromised immune system, and chronic medical conditions, can also influence the decision making.

Examination of the patient generally starts with observation of the individual's gait. Factors that contribute to the ultimate plan include general conditioning (for instance, is the patient obese?). The examination should also include an assessment of motion and stability of the major lower extremity joints. Limitation of joint motion or instability can have a direct impact on both the etiology and the treatment of deformities. For example, a hip adduction contracture can lead to the development of knee valgus in patients and attempts to correct the knee valgus without addressing the hip adduction contracture can lead to gait problems after correction of the knee deformity as

M.L. Miller, MD • J.E. Gordon, MD (✉)
Department of Pediatric orthopedic Surgery,
St. Louis Children's Hospital, One Children's Place
Suite 4S60, St. Louis, MO 63110, USA
e-mail: millerma1@wudosis.wustl.edu;
gordone@wudosis.wustl.edu

well as postoperative recurrence. Children with congenital limb length discrepancies frequently have hip, knee, and/or ankle instability of the shorter extremity, which can have a substantial impact on subsequent limb lengthening. Additionally, rotational profile should be assessed by physical examination, documenting femoral anteversion [1] and tibial torsion clinically.

Imaging studies provide information about the static deformity in both the anteroposterior and lateral planes. It is crucial when evaluating the radiographs that the surgeon ascertains not only the presence of malalignment, but also the location of one or more deformities. This can be best accomplished by either mechanical axis planning or anatomic axis planning utilizing full-length radiographs of the entire lower extremity including the hip, knee, and ankle. This portion of the evaluation has been addressed in the previous chapter. Components of the deformity can include angulation, translation, length, and rotation. Of these components, angulation, translation, and length can be largely described from the radiographs. Rotation is often best ascertained by examining the patient, although specialized rotational studies such as CT scans and MRI can complement the physical examination in selected situations.

One must elucidate why the patient and/or family are seeking medical care for their deformity. Is the patient simply bothered by the appearance of the extremity or is the patient having pain? Often families seek care for growing children because of concerns not about the current state of the limb but because of concerns that the deformity will worsen or that pain or disability will result at a later time. It is important to engage the patient and caretaker regarding the natural history of the deformity and counsel them as to how the surgical correction may or may not address their concerns. Occasionally the patient or caretaker may be seeking care for a complaint that is only minimally or not related to the patient's deformity.

One must also evaluate the social situation of the patient as well as the psychological issues and family dynamics when planning correction of a deformity. In particular, the surgeon should take into account the ability of the patient and family to comply with a proposed treatment regimen. For example, gradual correction of deformities utilizing a circular external fixation system in a patient with autism might be ill advised. The ability of patients and families to comply with postoperative protocols should be evaluated prior to finalizing a surgical plan and prearrangements for the anticipated need for physical therapy and follow-up visits may be necessary in certain situations. The surgeon's skill set and available medical resources should also be taken into account when developing a plan. Relevant cultural norms should also be considered and may dictate pursuing reconstructive options that might otherwise be contraindicated and lead the surgeon and patient to accept perhaps less function in order to be more culturally acceptable. For example in

Table 3.1 Important elements of a problem list to describe in planning a lower extremity deformity correction

Uniapical deformity versus multiapical deformity
Coronal, sagittal, and rotational parameters of each deformity
Soft-tissue envelope/vascularity of bone
Patient/caretaker perception of problem
Patient comorbidities
Prior treatment successes and challenges

some parts of the world there is a strong cultural bias against accepting amputation as part of what otherwise might be a preferred treatment.

The Problem List

The history, physical examination, imaging studies, patient and family perceptions of the problem, and dynamics of the situation should be brought together by the surgeon to form a problem list (Table 3.1). This list should summarize the deformities, pertinent pathology, and comorbidities as they impact the treatment of the deformity, patient perceptions of the problem, and potential obstacles to treatment whether they are related to the patient or the environment in which treatment is occurring. It is important to remember that the problem list is simply a problem list and not necessarily a surgical agenda.

After a problem list has been developed, the anatomy and biology of the underlying deformity must be considered. In particular the surgeon should decide whether the location of the deformity is more amenable to acute or gradual correction based on the anatomy of the neurovascular structures and postoperative or posttraumatic scarring. Are the physes open, leaving the option of growth modulation to correct the deformity? The presence of active or prior infection is another important factor to be considered, as are factors such as the presence of a pseudarthrosis.

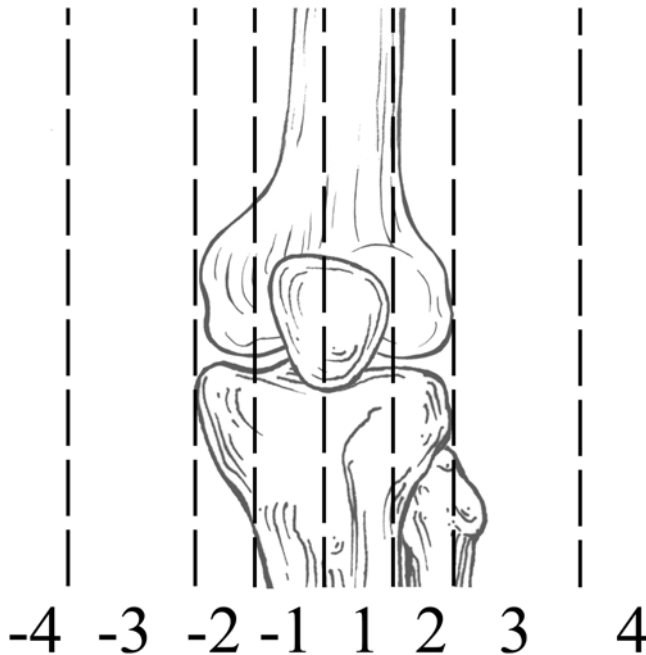
When considering the problem list in conjunction with the anatomy and biology of the problem, the surgeon should be able to outline options for an appropriate treatment agenda for addressing the deformity comprehensively over time. Some of these plans may be relatively simple comprising an acute correction of a uniapical deformity. Other cases may require a much more complex plan, including a series of interventions over a number of years such as for an infant with proximal femoral focal deficiency.

Surgical Indications: General

The decision about whether or not to correct a given deformity can be quite individual for each patient and there are no absolute rules. Relative indications for surgical correction of a deformity include the presence of pain or a deformity

Table 3.2 Relative indications for surgical correction of lower extremity deformity

Persistent pain
Mechanical axis in zone 2 with symptoms
Mechanical axis in zone 3 or greater with or without symptoms
Uncompensated symptomatic hindfoot deformity
Sagittal plane deformities impeding gait and function

**Fig. 3.1** Depiction of zone of mechanical axis deviation at the knee. Zone 1 is within the tibial spine. Zone 2 is within the tibial condyles. Zone 3 is within the knee joint width away from the center of the knee joint. Zone 4 is greater than one knee joint width from center of knee joint [22]

with a natural history of substantial progression (Table 3.2). In general, current or anticipated limb length discrepancies greater than 2 cm should be addressed.

Surgical Indications: The Knee

Angulatory deformities about the knee should generally be corrected if the mechanical axis falls within zone 2 and the patient is symptomatic and should be corrected if the mechanical axis is beyond zone 2 (Fig. 3.1) even if the patient is asymptomatic. When the deformity about the knee requires correction, the joint orientation angles such as the lateral distal femur angle (LDFA), the medial proximal tibial angle (MPTA), and the joint line congruency angle (JLCA) should be measured. If the JLCA is more than 5° in conjunction with a bony deformity, we prefer to address the ligamentous laxity as well. If the deformity about the knee involves

only the femur or the tibia and the other bone is normal, correction should nearly always occur within the affected bone. If both bones are abnormal but the majority of the deformity is within one of the bones, there may be some consideration to correcting only the bone with the majority of the deformity if less than 5° of abnormality is present in either the LDFA or MPTA. If greater than 5° of abnormality is noted in both the LDFA and MPTA, we prefer to address the deformity at both sites.

For sagittal plane deformities about the knee, one must consider both the bony deformity within the distal femur and proximal tibia as well as the soft-tissue constraints about the knee joint. The goal of treatment of sagittal deformity about the knee is functional range of motion in both extension and flexion. My preference is to develop a surgical plan that achieves knee extension within 5° of full extension and without hyperextension of greater than 5° as well as knee flexion of at least 90°. For patients with limited extension, one must consider concomitant hamstring, ilio-tibial band, or posterior capsule releases while correcting the bony sagittal deformity. Likewise, one can consider quadriceps lengthening to augment a deformity correction in a patient with limited knee flexion.

Surgical Indications: The Ankle

The decision to correct ankle alignment must be made in conjunction with a careful examination of the hindfoot. Patients with substantial deformity of the ankle may be clinically well aligned with a compensatory hindfoot deformity (Fig. 3.2). Patients with such well-compensated deformity and with limited subtalar motion may not be well served by a decision to correct the ankle and thus “create” a more visible deformity by uncovering the fixed hindfoot abnormality.

Relative Contraindications

Contraindications to surgery are necessarily somewhat vague and include a number of patient-related factors including unrealistic expectations on the part of the patient and caretakers, their inability to follow through with the necessary outpatient components of a treatment program, as well as situations where the risks of surgical intervention outweigh the potential benefits to the patient (Table 3.3). For instance, patients with severe mental illness or with limited ability to comprehend the treatment plan may not have the ability to comply with more complex treatment protocols including gradual correction using external fixation. Although more complex treatment protocols may be contraindicated in these patients, simplified alternatives may represent better choices. For example, for some patients the

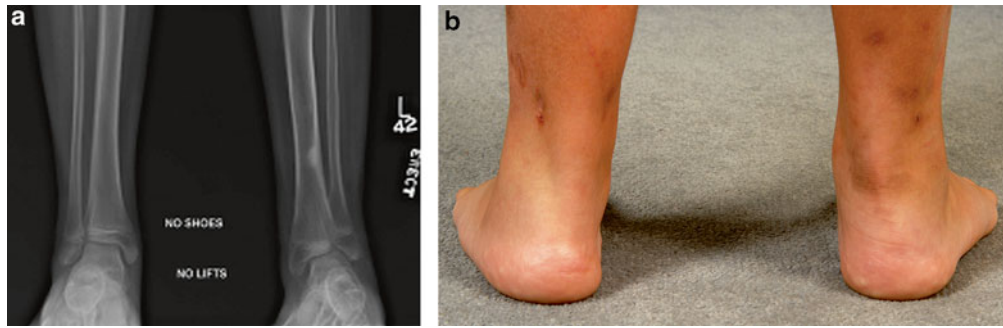


Fig. 3.2 Radiographs (a) and clinical images (b) of a patient with distal tibial valgus and compensatory hindfoot varus. Note the radiographic valgus of the left ankle and the apparent normal clinical alignment of the left hindfoot

Table 3.3 Relative surgical contraindications to performing lower extremity deformity correction

Unrealistic patient/family expectations
Patient/family unable to comply with postoperative protocol
Potential complications of treatment outweigh benefits to patient

difficulties involved in complying with instructions and a physical therapy program associated with a limb lengthening may be able to comply easily with the less strenuous instructions and therapy associated with a closed femoral shortening (Fig. 3.3).

Surgical Options

The plan for each deformity may comprise any of a number of different techniques that might be applicable in a given situation (Table 3.4). There is no compelling reason to avoid combining techniques when clinically applicable. General categories that should be considered include soft-tissue surgery, physal bar resection, growth modulation, acute correction with internal or external fixation, or gradual correction with external fixation. A brief description of the techniques follows with a general description of indications and contraindications.

Soft-Tissue Modification

Soft-tissue surgery can be effective either as a solitary procedure or in conjunction with bony surgery. Modification of the soft tissues is not limited to procedures that directly approach the soft tissues themselves but can also be an intended consequence of bony procedures. In particular, tightening of the lateral collateral ligament at the knee can be performed by translating the fibular head distally either with a fibular osteotomy and gradual bone transport with an external fixator or in cases of adolescent tibia vara utilizing

a circular external fixator. In these cases a tibial osteotomy can be performed while leaving the fibula intact and securing it distally to the tibia. The angulatory deformity is then corrected while lengthening gradually, thus transporting the fibula distally in relation to the proximal tibia resulting in tightening of the lateral collateral ligament (Fig. 3.4).

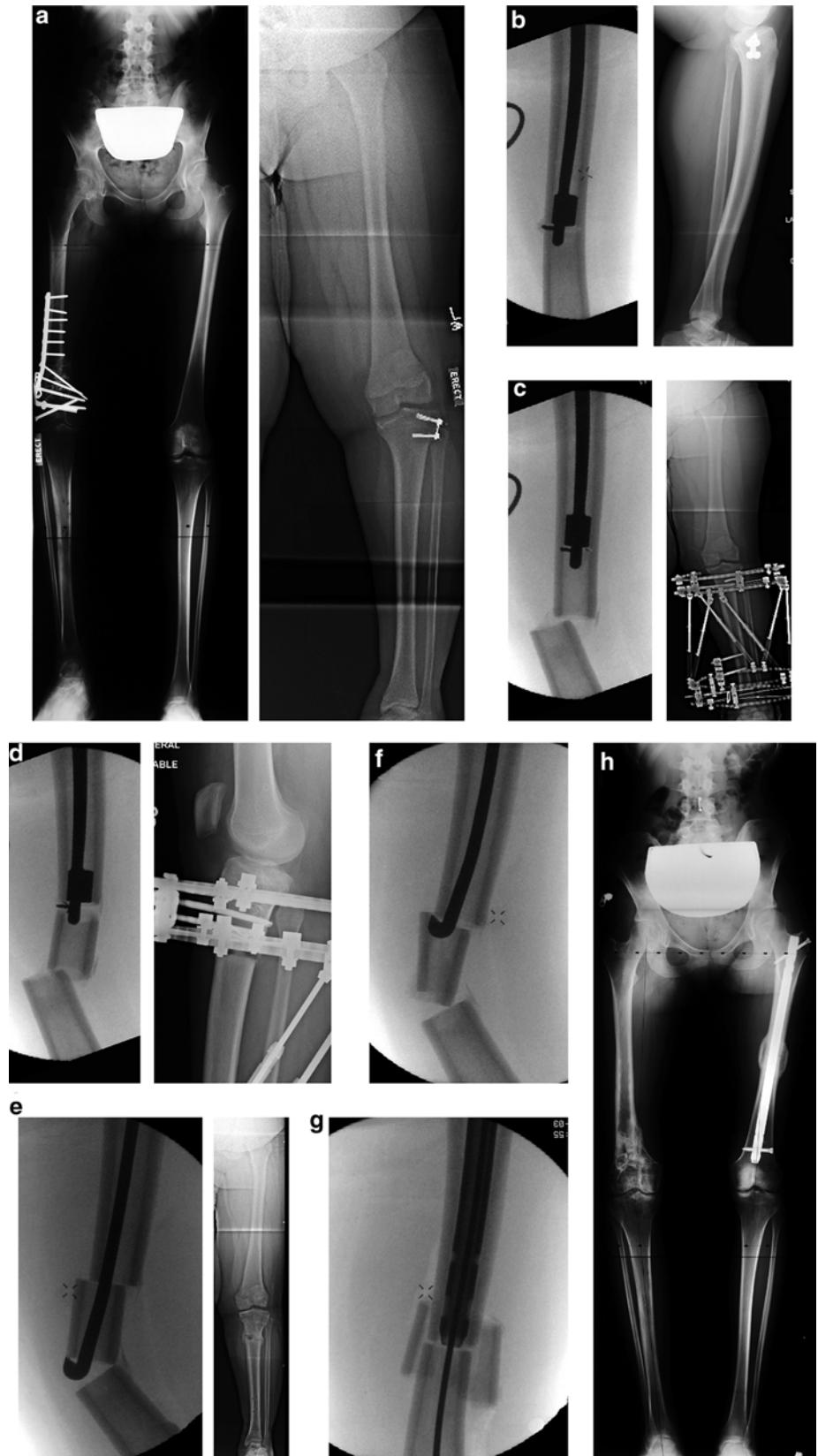Physal Modulation or Ablation

Physal modulation can take many forms. Physal bar resection following traumatic or developmental partial arrest can be performed successfully in situations where a partial arrest of the physis, as documented by progressive deformity, is present that involves less than 50 % of the physis with more than 2.5 cm of growth remaining at the involved physis and more than 2 years of growth expected [2, 3]. Advantages of physal bar resection include the relative simplicity involved in postoperative care and relatively rapid patient recovery and return to activity (Fig. 3.5). Disadvantages of physal bar resection include a high failure rate and frequent late closure of the physis necessitating close follow-up and further surgical treatment.

Complete epiphysodesis by percutaneous drilling or utilizing either plates or staples can be performed in skeletally immature individuals who have adequate growth remaining to contribute to the correction of a limb length discrepancy [4]. This has been recommended in situations where the projected limb length discrepancy is between 2 and 5 cm. The technique however can be utilized in larger limb length discrepancies as part of a comprehensive treatment plan. Temporary hemiepiphysodesis using medial and lateral staples or plates has been reported [5] but is not widely utilized due to concerns about permanent physal closure and possibility of rebound growth following implant removal.

Hemiepiphysodesis by plate, screw, drilling, or Blount's staples should be considered in patients who are skeletally immature and who have adequate growth available to reasonably expect correction of an angulatory deformity [6].

Fig. 3.3 Femoral shortening case study. **(a)** Preoperative radiographs of a 17-year-old female with a 7 cm left greater than right limb length discrepancy due to a right-sided posttraumatic femoral growth arrest. **(b)** Intramedullary saw completing distal cut within femur. **(c)** Intramedullary saw beginning proximal cut within femur 7 cm proximal to distal cut. **(d)** Completion of proximal intramedullary cut. **(e)** Intramedullary wedge splitting the medial cortex of the intercalary segment. **(f)** Completion of splitting intercalary segment. **(g)** Reduction of proximal and distal segment with solid intramedullary nail. **(h)** Postoperative radiographs demonstrating healed femur after closed femoral shortening

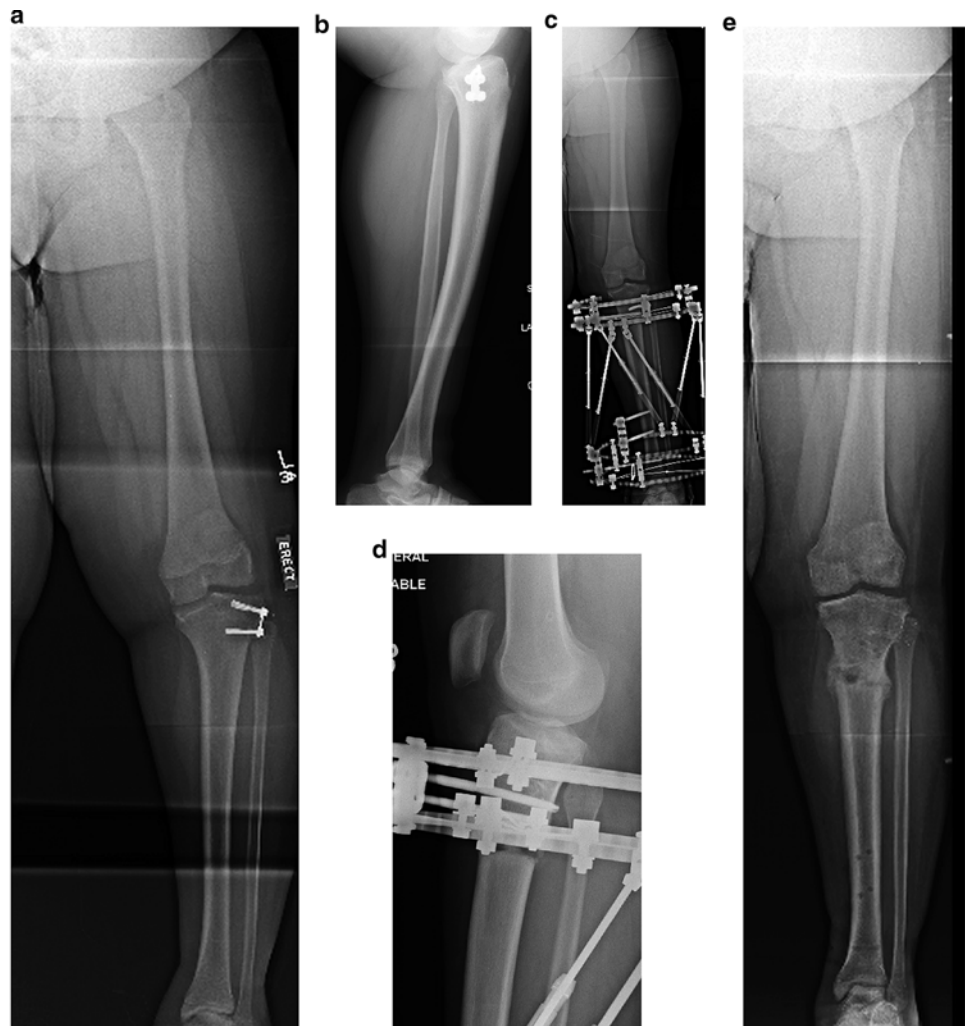

These deformities can be in the coronal, sagittal, or oblique planes (Fig. 3.6). Physeal modification can be utilized even in situations where the physis is abnormal [7] such as chronic renal failure and hypophosphatemic rickets. Deformities such as proximal tibial valgus following a Cozen's-type fracture which tend to recur following osteotomy correction are particularly amenable to treatment with plate hemiepiphysiodesis. Following correction of the deformity in a patient who has substantial growth remaining, the metaphyseal screw can be removed percutaneously and the plate and epiphyseal screw can be left in place allowing continued growth (Fig. 3.7). If the deformity recurs, the metaphyseal screw can be replaced percutaneously resulting in re-hemiepiphysiodesis and repeat correction.

Table 3.4 Available techniques to perform deformity correction

Soft-tissue modification
Physeal modulation or ablation
Osteotomy with acute correction
Osteotomy with gradual correction

Fig. 3.4 Case example of adolescent tibia vara treated with circular external fixator and tightening of the lateral collateral ligament. (a, b) AP and lateral preoperative radiographs of a 12-year-old male with tibia vara. (c, d) Immediate postoperative radiographs depicting a ring circular external fixator with fixation of the fibula distally into the tibia and no proximal transfibular fixation. (e) Postoperative radiographs after fixator removal showing distal transport of the fibula relative to the proximal tibia, thus tightening the lateral collateral ligament



Acute Correction with Osteotomy

Osteotomies with acute correction are particularly indicated in angulatory deformities in patients with minimal limb length discrepancies allowing correction of the deformity without placing undue stress on the neurovascular structures. Most often the acute correction is combined with rigid internal fixation although it can be utilized in conjunction with external fixation or Kirschner wire fixation and cast immobilization. The choice of implants is determined by the site of the osteotomy and can potentially include intramedullary fixation, screw fixation, locking plates, or non-locking plates.

Intramedullary fixation can be helpful when combined with percutaneous diaphyseal osteotomy techniques such as in patients with an isolated femoral rotational deformity [8, 9]. Intramedullary stabilization can also be helpful when angulatory deformities exist in the diaphyseal region after either traumatic malunion or in cases of hypophosphatemic rickets with residual femoral lateral bow (Fig. 3.8). In these cases often the percutaneous osteotomy can correct both the apparent genu varum deformity and the coxa vara that

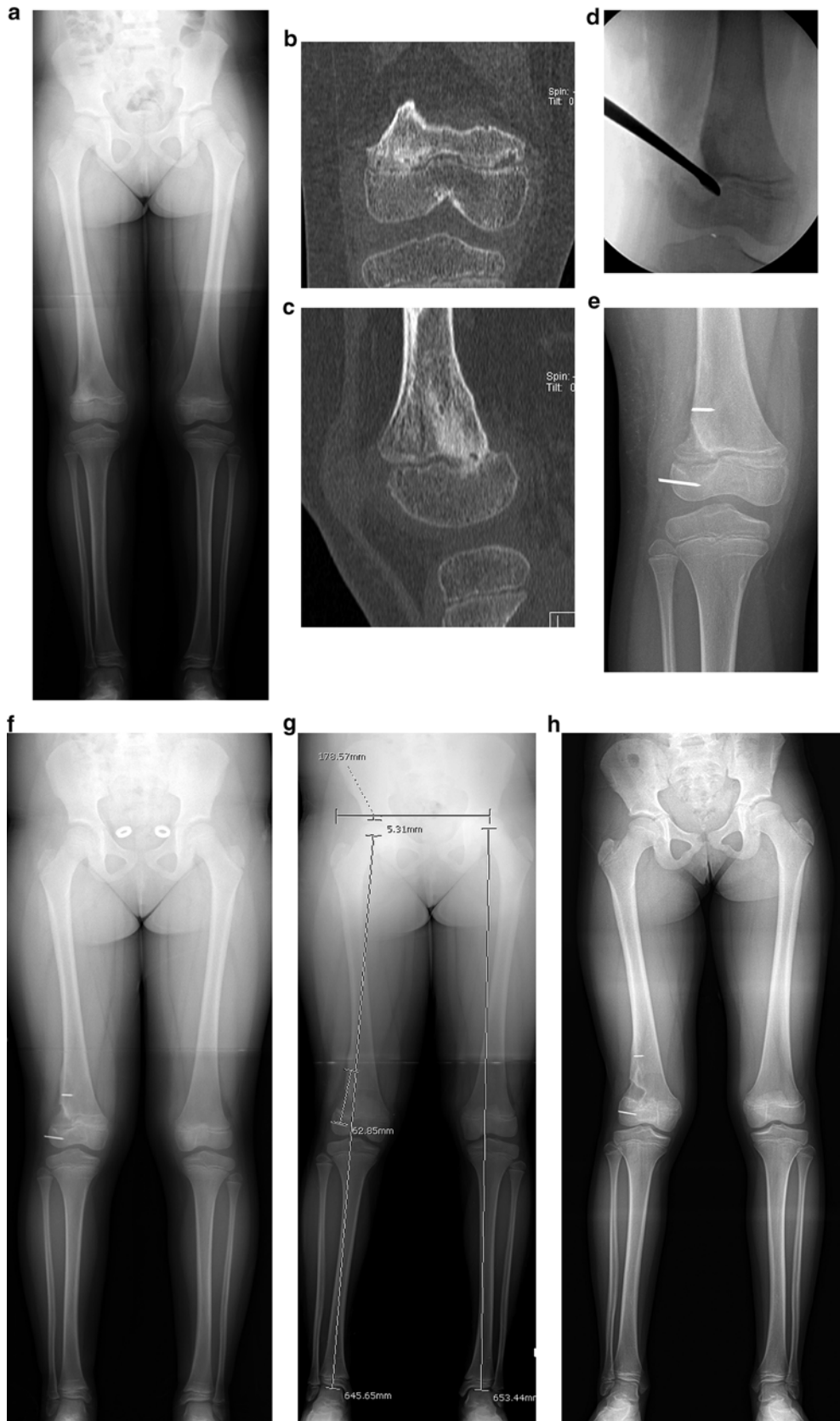

Fig. 3.5 Case example of a 9-year-old female with a posttraumatic physal bar formation in the right distal femur. **(a)** Standing AP demonstrating right distal femur physal bar. **(b, c)** Coronal and sagittal slice of a CT scan showing lateral distal femoral bar with less than 20 % of physis involvement. **(d)** Fluoroscopic image showing curettage of physal bar. **(e)** Postoperative AP after physal bar resection. K-wires are placed in order to follow eventual growth; radiolucent cranioplast is

placed on the epiphyseal side to limit reformation of bar. **(f)** Immediate postoperative standing AP. **(g)** Standing radiographs demonstrating growth within the distal femoral physis 2 years postoperatively. **(h)** Standing anteroposterior radiograph demonstrating continued growth with migration of the cranioplast proximal to the physis with resultant recurrence of the physal bar associated with a limb length discrepancy and valgus deformity 3 years postoperatively

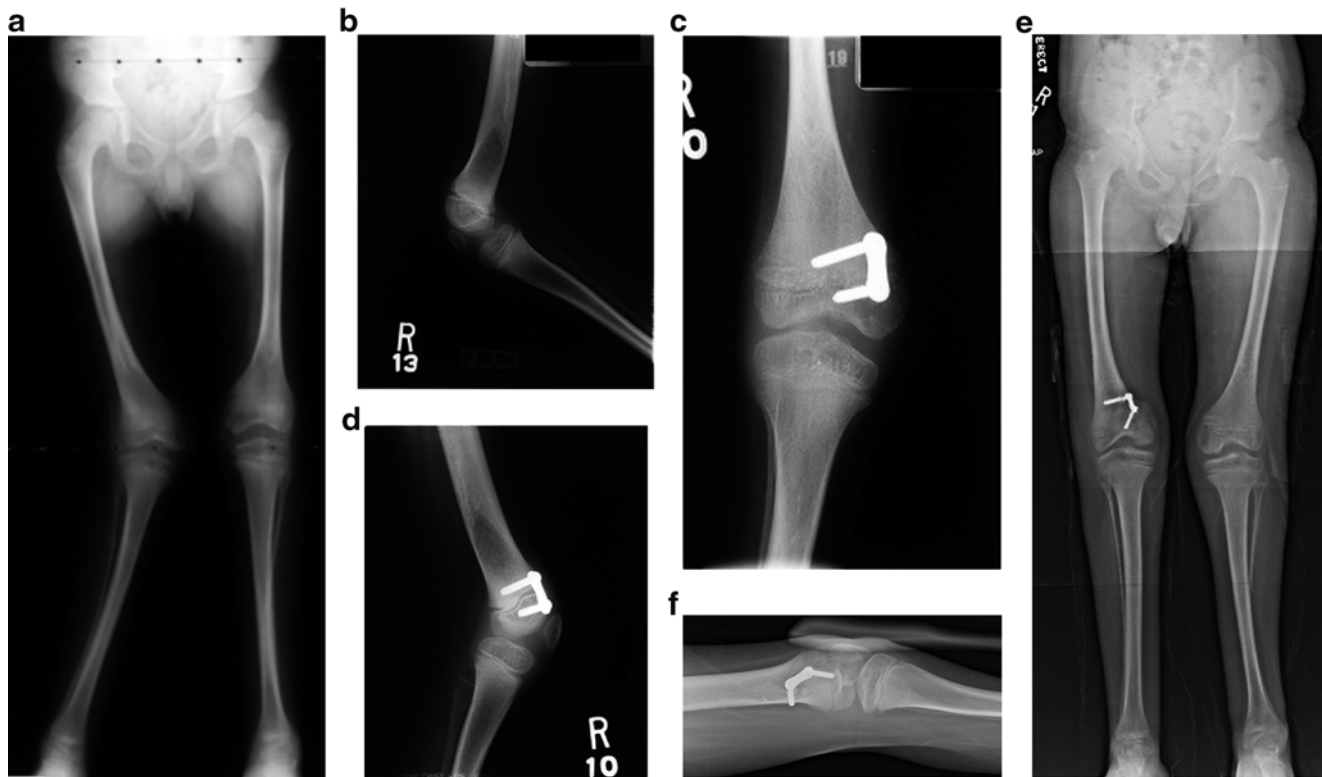

Fig. 3.6 Oblique plane deformity of the right distal femur in a 6-year-old male with arthrogyposis. (a) Standing AP demonstrating right distal femoral valgus. (b) Lateral of the right knee in less than maximal extension showing a knee flexion contracture of approximately 25°. (c, d) AP and lateral of the knee showing hemiepiphyseodesis of the antero-

medial distal femur, promoting distal femoral varus and procurvatum. (e, f) Standing AP and maximal extension lateral views 18 months post-operatively with resultant correction of deformity. The patient had full knee extension

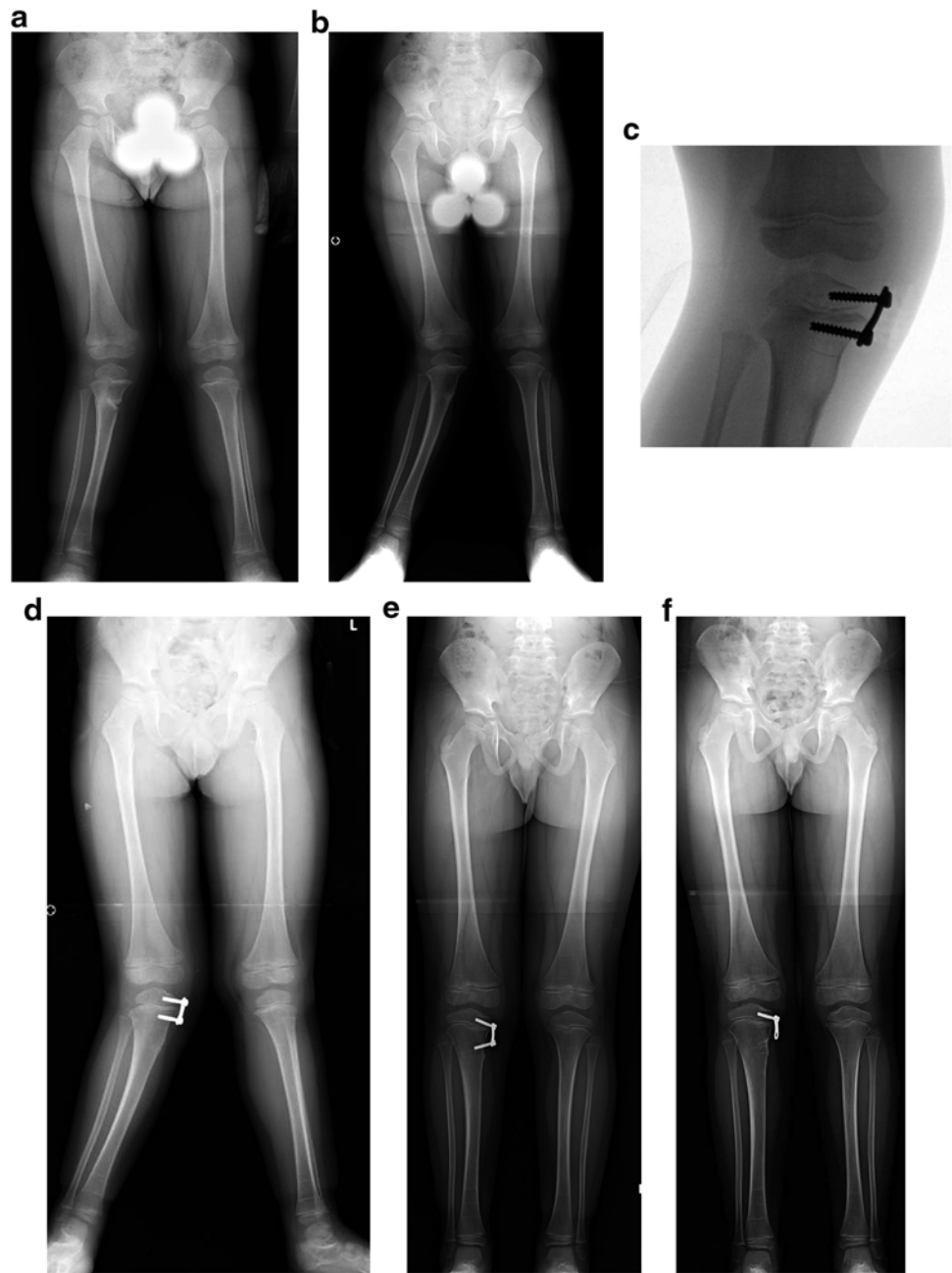
can produce a significant abductor lurch during gait. The disadvantage of intramedullary fixation is the limitation in the magnitude of the correction that can be obtained. Intramedullary stabilization results in a comparatively straight diaphyseal segment when combined with a diaphyseal osteotomy. Intramedullary stabilization can also be utilized with blocking screws in conjunction with acute correction of a supracondylar distal femoral or proximal tibial osteotomy but this use is technically difficult for the surgeon who is not familiar with the use of such screws. Proper mechanical alignment of the proximal and distal segments can also be obtained with temporary external fixator assistance prior to intramedullary reaming and fixation with an intramedullary nail. Other contraindications to intramedullary fixation include open physes with substantial remaining growth in the proximal tibia and the inability to pass an intramedullary nail through an obstructed intramedullary canal. In addition intramedullary nail should be generally avoided in the presence of active infection.

Screw fixation provides the surgeon with the ability to stabilize osteotomies with some inherent bony stability while achieving rigid correction of the deformity. Cannulated screws are particularly helpful when performing osteotomies

in the epiphyseal region that require rigid control of the osteotomy. One specialized use of these screws is to stabilize intra-articular osteotomies in the proximal tibia. This can be performed in cases of medial tibial plateau depression due to delayed treatment of early-onset tibia vara with a resulting “pagoda” deformity [10]. These tibial plateau osteotomies can be effectively stabilized after an acute correction using cannulated screws with an incomplete osteotomy and allograft cortical bone as a structural graft (Fig. 3.9).

Plates provide a rigid method of stabilizing osteotomies following an acute correction. They are particularly useful in stabilizing metaphyseal osteotomies after correction of either angulatory or rotational deformities. Plates utilized can be conventional plates, locking plates, or blade plates [11]. In particular, blade plates and locking plates (Fig. 3.10) can be used to stabilize osteotomies that have little or no inherent stability and locking plates can be utilized with a submuscular technique that may minimize soft-tissue dissection. Advantages to their use include the ability to begin early motion at adjacent joints, rigid fixation, and immediate correction of the deformity (Fig. 3.11). Disadvantages to the use of conventional plates are the relatively larger amount of soft-tissue dissection that is necessary, the lack of ability to

Fig. 3.7 Four-year-old male with a proximal tibial valgus deformity after proximal tibia fracture (Cozen's fracture). **(a)** Standing AP after cast treatment for right proximal tibia fracture. **(b)** 6-month postinjury film demonstration proximal tibial valgus deformity. **(c)** Fluoroscopic image showing placement of hemiepiphysiodesis plate medially. **(d)** Immediate postoperative standing AP. **(e)** 9-month postoperative radiographs showing normal mechanical axis. **(f)** Metaphyseal screw is removed after deformity correction in order to facilitate replacement of hemiepiphysiodesis if deformity recurs



adjust the correction postoperatively, and the difficulties associated with soft-tissue coverage in areas with little overlying soft tissue with resulting issues with infection.

Gradual Correction with Osteotomy

The workhorse of complex deformity correction is gradual correction. Gradual correction is effective in treating deformities with components of angulation, rotation, translation, and/or length. Gradual correction can be achieved with

monolateral external fixation, circular external fixation utilizing the classic Ilizarov-type hinges and distractors, or computer-controlled six-strut circular external fixation. Most recently, self-lengthening nails have combined some of the advantages of gradual correction with internal fixation [12]. Self-lengthening nails however provide no ability to correct angulatory deformities gradually but do allow for acute correction of angulatory deformities with gradual lengthening. Advantages of gradual correction include minimal soft-tissue dissection and early weight bearing with the ability to deal with problems that arise during the postoperative period and

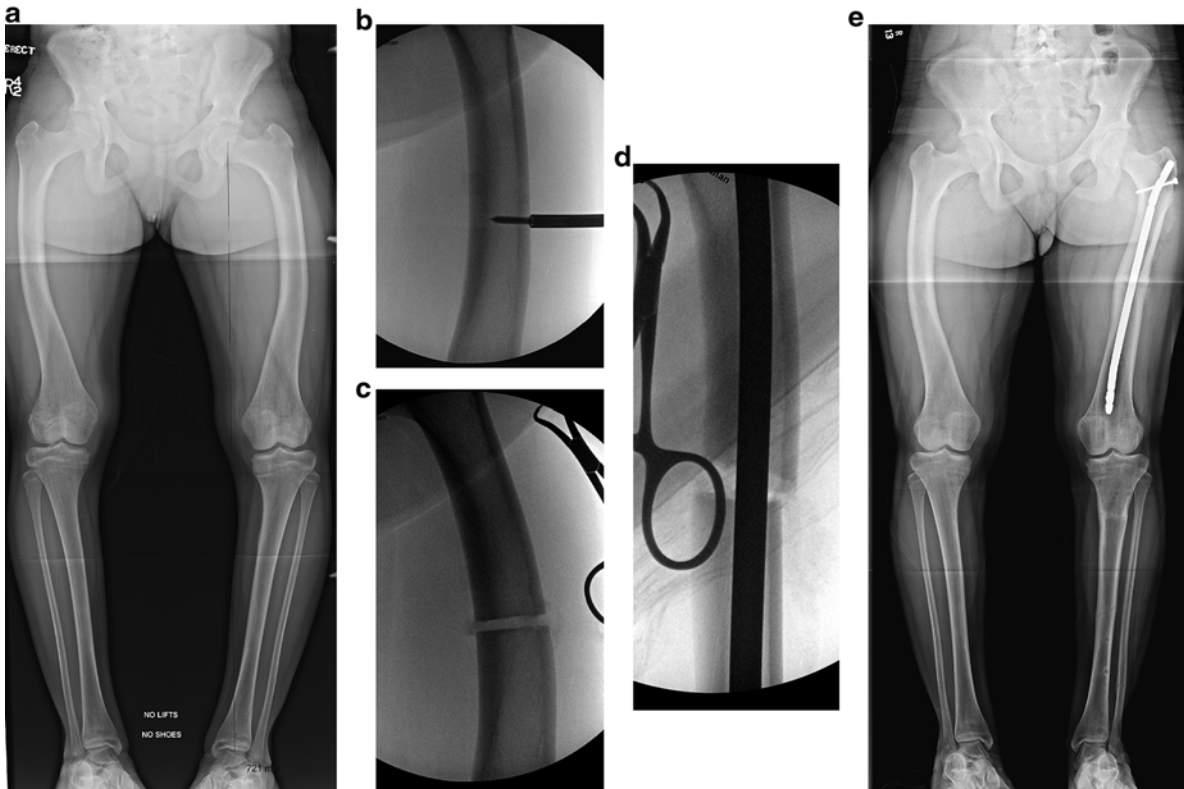


Fig. 3.8 Use of intramedullary nail for deformity correction. (a) Standing AP of 12-year-old female with X-linked hypophosphatemic rickets and midshaft bowing of both femurs at the isthmus. (b) Fluoroscopy demonstrating percutaneous diaphyseal femoral osteotomy using drill. (c) Completion of diaphyseal femoral osteotomy. (d) Insertion

of pediatric femoral nail. As the osteotomy was performed at the isthmus and deformity, this results in an opening wedge osteotomy medially. (e) Postoperative standing AP demonstration correction of right femoral deformity. A proximal tibial osteotomy with gradual correction using a circular external fixator was used to correct the tibial deformity

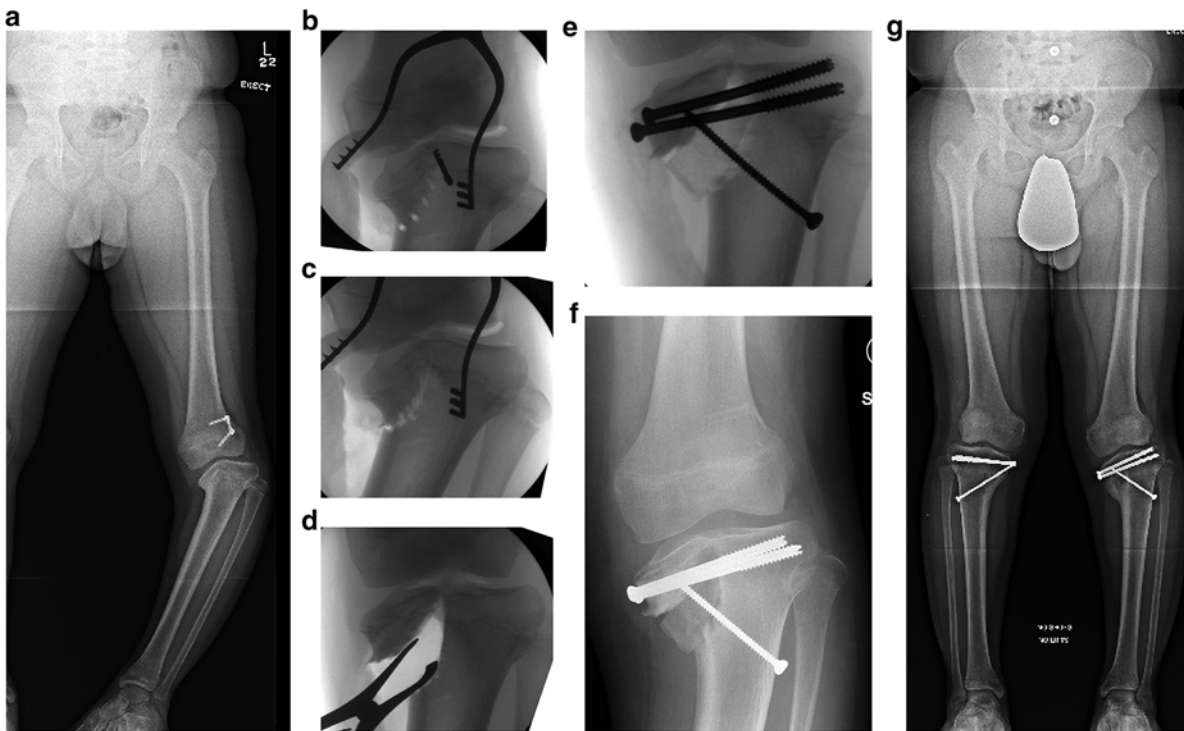


Fig. 3.9 Twelve-year-old male with Blount's disease and proximal tibia intra-articular deformity. (a) Standing AP demonstrating intra-articular proximal tibial deformity and medial growth arrest (Langenskiöld type VI). (b, c) Fluoroscopy demonstrating drill holes along the path of intra-articular osteotomy for tibial plateau elevation, completion of osteotomy with an osteotome. (d) Laminar spreader

simulating correction of intra-articular deformity. (e, f) Intraoperative fluoroscopy and postoperative radiographs demonstrating fixation with large fragment screws after structural bone graft placement. (g) Healed osteotomy sites with persistent proximal tibial varus. Tibial plateau elevation corrects intra-articular deformity but often does not correct overall varus deformity completely

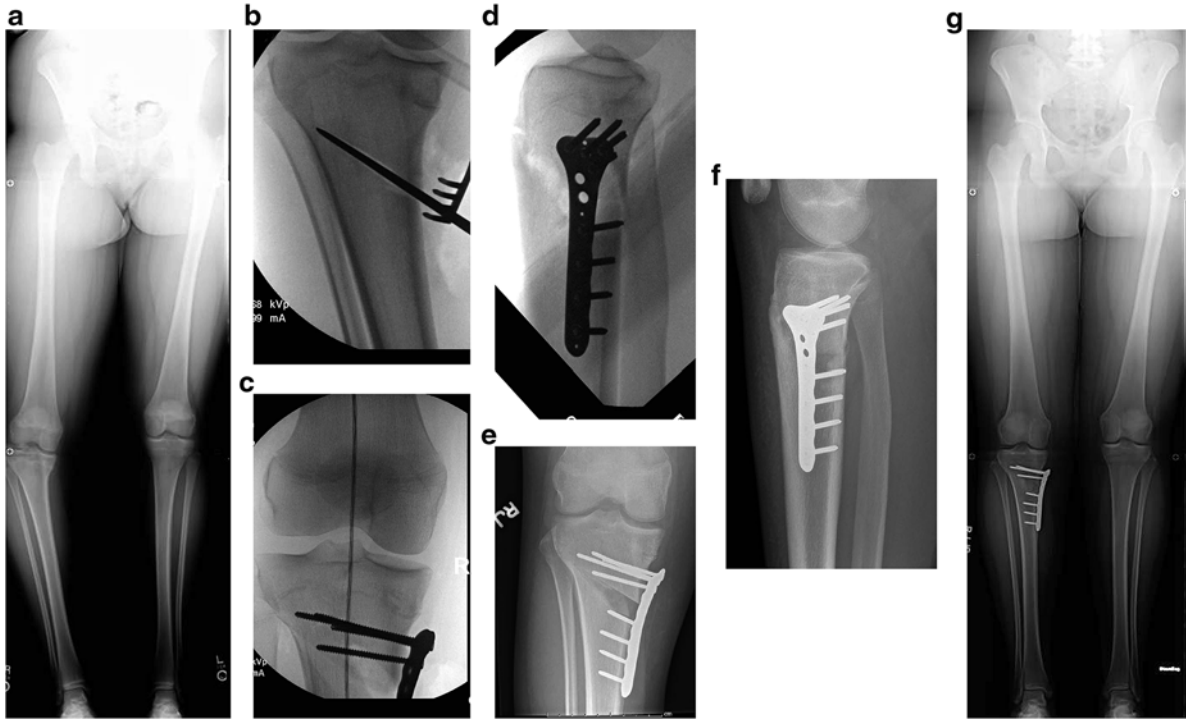


Fig. 3.10 Fourteen-year-old female with Blount's disease. (a) Standing AP demonstrating right proximal tibia varus deformity. (b) Oblique osteotomy heading from distal medially to proximal laterally with care to preserve lateral cortex. (c) Fluoroscopic image demonstrating restoration of mechanical axis. (d) Lateral fluoroscopic view. (e, f) Postoperative AP and lateral view showing correction of deformity. (g) 18-month postoperative standing AP demonstrating deformity correction

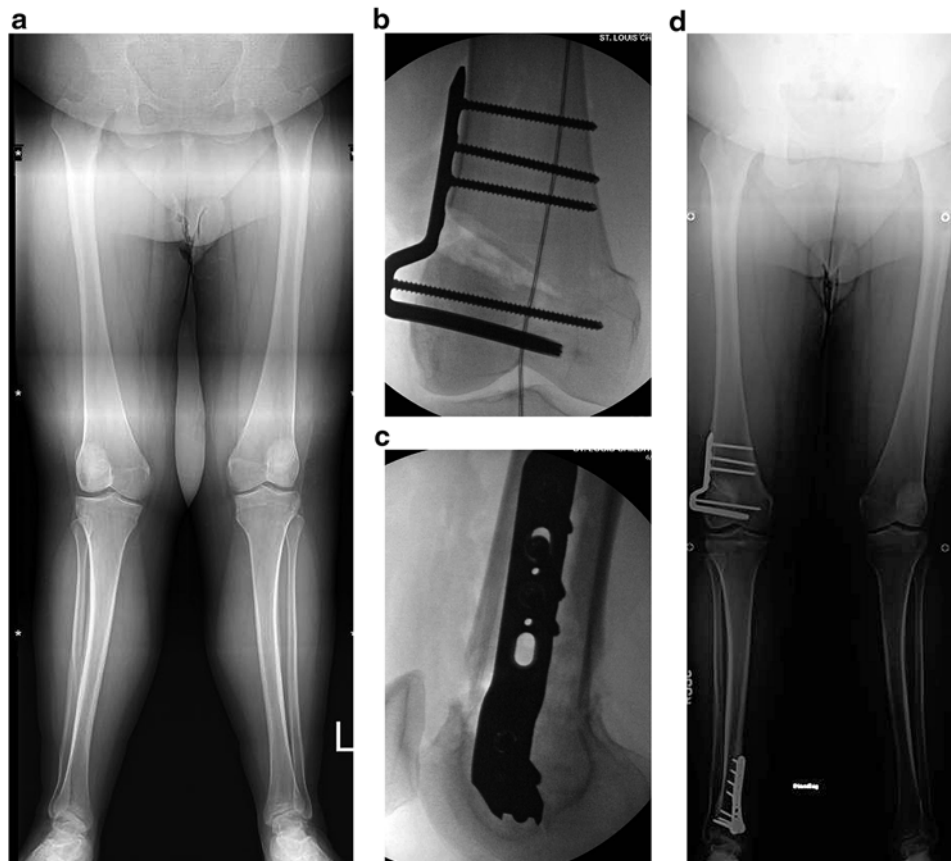
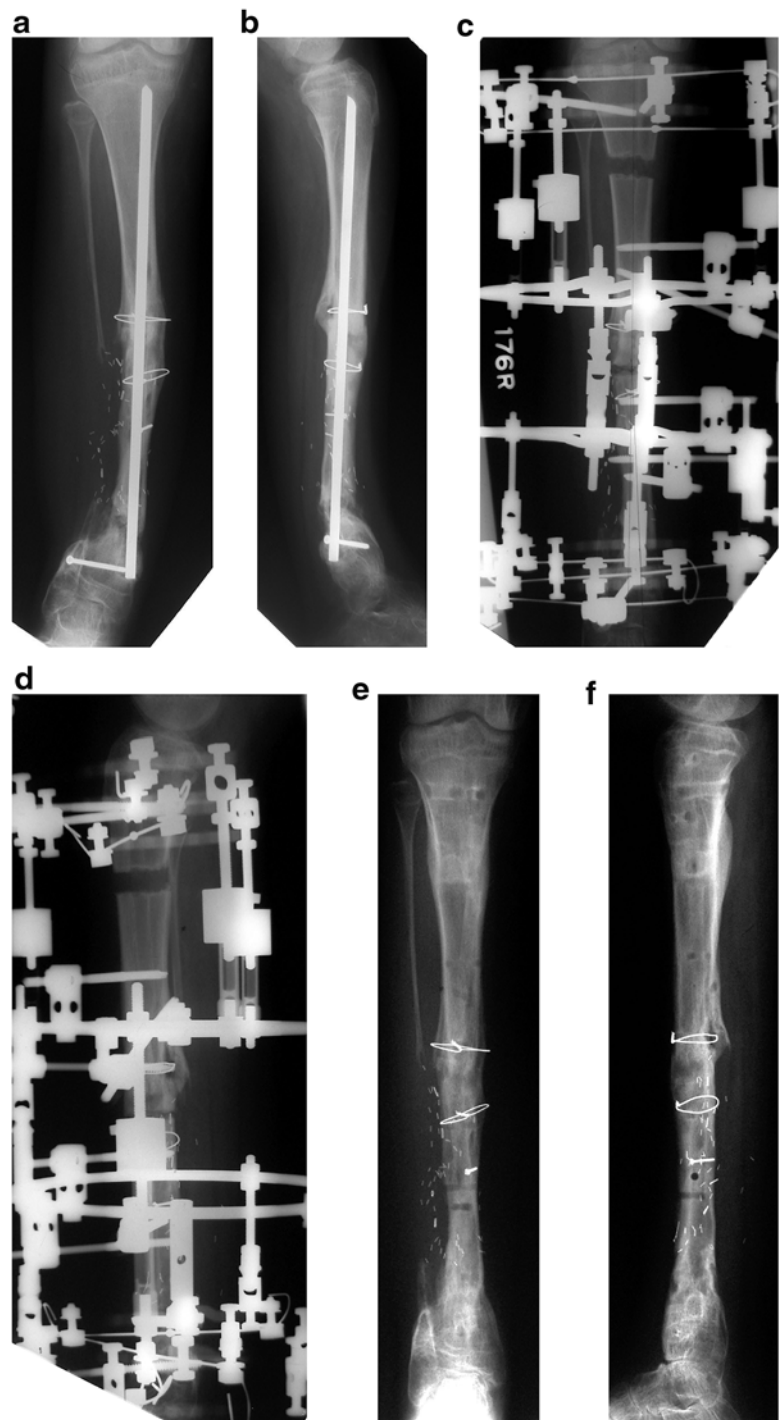


Fig. 3.11 Sixteen-year-old female with distal femoral valgus deformity. (a) Standing AP demonstrating distal femoral valgus deformity. (b, c) AP and lateral fluoroscopic images showing distal femoral osteotomy with blade plate correction of deformity. (d) Postoperative radiographs demonstrating restoration of mechanical axis. Of note, patient had a concomitant derotational distal tibial osteotomy for excessive external tibial torsion

Fig. 3.12 Thirteen-year-old female with tibial pseudarthrosis, status post-multiple attempts at correction and healing with Peter Williams rod. (a, b) AP and lateral of the right tibia demonstrating deformity and occurrence of a new distal tibial pseudarthrosis. (c, d) AP and lateral views of Ilizarov application with multilevel osteotomy, proximal osteotomy for tibial lengthening, and distal tibial osteotomy for deformity transport into pseudarthrosis site. (e, f) AP and lateral views after frame removal and pseudarthrosis healing



the ability to “fine-tune” the correction to optimize final alignment [13–16]. Disadvantages of gradual correction include complex postoperative care requiring substantial compliance with a physical therapy protocol and rigid adherence to a follow-up schedule by the patient and family with the possibility of damaging adjacent joints by the injudicious use of distraction at an osteotomy site. In addition, external fixation

systems tend to be disliked by patients and issues with pain and pin tract problems are often noted [17–21]. As the lower limb deformities become more complex, the degree of required patient compliance and the physician learning curve also increase substantially. The trade-off, however, is the increasing ability to deal with complex three-dimensional deformities and achieve accurate corrections (Figs. 3.12 and 3.13).

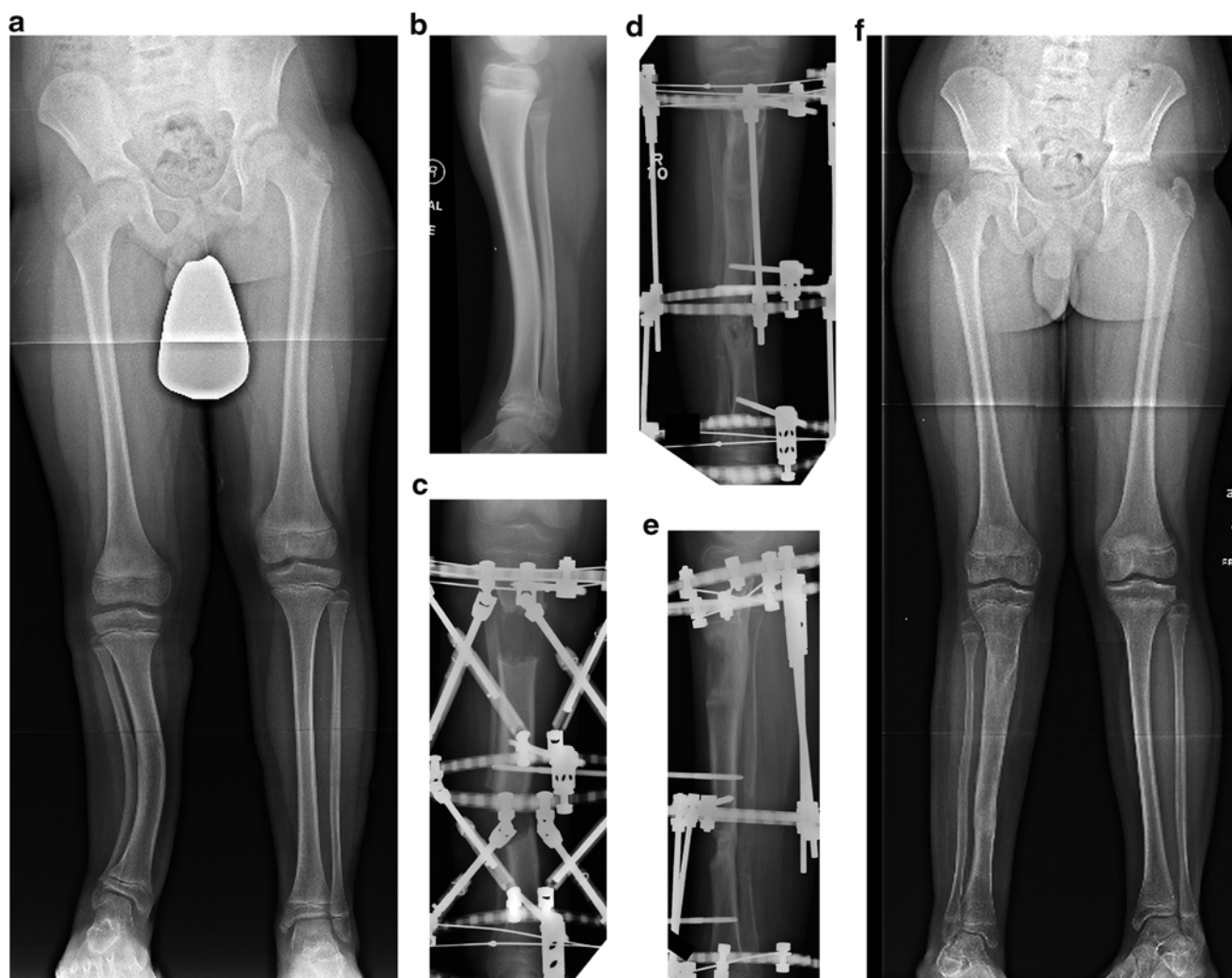

Fig. 3.13 Ten-year-old male with posteromedial bowing and limb length discrepancy. (a, b) Standing AP and lateral view demonstrating deformity and limb length discrepancy. (c) AP radiograph showing application of bi-level circular external fixator. A proximal tibial oste-

otomy was performed for lengthening and a midshaft osteotomy for deformity correction. (d, e) AP and lateral view demonstration of healing of regenerate and correction of deformity. (f) Standing AP showing restoration of mechanical axis and correction of leg length discrepancy

Summary

In summary, decision making in lower extremity deformity correction is a necessary but arduous task. One must develop a complete problem list which addresses the pertinent difficulties associated with the patient's deformity, perceived problem, and ability of the caretaker and patient to implement the plan of care. This problem list then should help guide the location of the correction and select which mode or combination of modes of deformity correction is optimal, whether it be soft-tissue modification, physcal modulation/ablation, or osteotomy though either an acute or gradual approach. The approach(es) selected should then guide the choice of implant. With advances in technology devices such as self-lengthening nails and computer-controlled six-strut circular external fixators

have become more readily available and accessible, and the complexity of deformities that can safely be addressed has increased dramatically. It is still important to start with a comprehensive evaluation of each patient and his or her environment and apply the principles of deformity correction to develop a customized treatment plan.

References

1. Ruwe PA, Gage JR, Ozonoff MB, DeLuca PA. Clinical determination of femoral anteversion. A comparison with established techniques. *J Bone Joint Surg Am.* 1992;74(6):820–30.
2. Kasser JR. Physcal bar resections after growth arrest about the knee. *Clin Orthop Relat Res.* 1990;255:68–74.
3. Langenskiold A. Surgical treatment of partial closure of the growth plate. *J Pediatr Orthop.* 1981;1(1):3–11.

4. Gabriel KR, Crawford AH, Roy DR, True MS, Sauntry S. Percutaneous epiphysiodesis. *J Pediatr Orthop.* 1994;14(3):358–62.
5. Skytta ET, Savolainen HA, Kautiainen HJ, Belt EA. Long-term results of leg length discrepancy treated with temporary epiphyseal stapling in children with juvenile chronic arthritis. *Clin Exp Rheumatol.* 2003;21(5):669–71.
6. Mielke CH, Stevens PM. Hemiepiphyseal stapling for knee deformities in children younger than 10 years: a preliminary report. *J Pediatr Orthop.* 1996;16(4):423–9.
7. Stevens PM, Klatt JB. Guided growth for pathological physes: radiographic improvement during realignment. *J Pediatr Orthop.* 2008;28(6):632–9.
8. Chapman MW, Dwellius PW, Bray TJ, Gordon JE. Closed intramedullary femoral osteotomy: shortening and derotation procedures. *Clin Orthop.* 1993;287:245–51.
9. Gordon JE, Pappademos PC, Schoenecker PL, Dobbs MB, Luhmann SJ. Diaphyseal derotational osteotomy with intramedullary fixation for correction of excessive femoral anteversion in children. *J Pediatr Orthop.* 2005;25:548.
10. Schoenecker PL, Johnston R, Rich MM, Capelli AM. Elevation of the medial plateau of the tibia in the treatment of Blount disease. *J Bone Joint Surg Am.* 1992;74(3):351–8.
11. Gordon JE, Heidenreich FP, Carpenter CJ, Kelly-Hahn J, Schoenecker PL. Comprehensive treatment of late-onset tibia vara. *J Bone Joint Surg Am.* 2005;87(7):1561–70.
12. Schiedel FM, Vogt B, Tretow HL, Schuhknecht B, Gosheger G, Horter MJ, et al. How precise is the PRECICE compared to the ISKD in intramedullary limb lengthening? *Acta Orthop.* 2014;85(3):293–8.
13. Feldman DS, Madan SS, Ruchelsman DE, Sala DA, Lehman WB. Accuracy of correction of tibia vara: acute versus gradual correction. *J Pediatr Orthop.* 2006;26(6):794–8.
14. Feldman DS, Madan SS, Koval KJ, van Bosse HJ, Bazzi J, Lehman WB. Correction of tibia vara with six-axis deformity analysis and the Taylor Spatial Frame. *J Pediatr Orthop.* 2003;23(3):387–91.
15. Feldman DS, Shin SS, Madan S, Koval KJ. Correction of tibial malunion and nonunion with six-axis analysis deformity correction using the Taylor Spatial Frame. *J Orthop Trauma.* 2003;17(8):549–54.
16. Gordon JE, Jani M, Dobbs M, Luhmann SJ, Szymanski DA, Schoenecker PL. Treatment of rigid hypertrophic posttraumatic pseudarthrosis of the tibia in children using distraction osteogenesis. *J Pediatr Orthop.* 2002;22(4):419–23.
17. Camathias C, Valderrabano V, Oberli H. Routine pin tract care in external fixation is unnecessary: a randomised, prospective, blinded controlled study. *Injury.* 2012;43(11):1969–73.
18. Dayton P, Prins DB, Hensley N, Wienke Jr J. A user-friendly method of pin site management for external fixators. *Foot Ankle Spec.* 2011;4(6):370–2.
19. Gordon JE, Kelly-Hahn J, Carpenter CJ, Schoenecker PL. Pin site care during external fixation in children: results of a nihilistic approach. *J Pediatr Orthop.* 2000;20(2):163–5.
20. Jennison T, McNally M, Pandit H. Prevention of infection in external fixator pin sites. *Acta Biomater.* 2014;10(2):595–603.
21. Lee CK, Chua YP, Saw A. Antimicrobial gauze as a dressing reduces pin site infection: a randomized controlled trial. *Clin Orthop Rel Res.* 2012;470(2):610–5.
22. Park SS, Gordon JE, Luhmann SJ, Dobbs MB, Schoenecker PL. Outcome of hemiepiphyseal stapling for late-onset tibia vara. *J Bone Joint Surg Am.* 2005;87(10):2259–66.